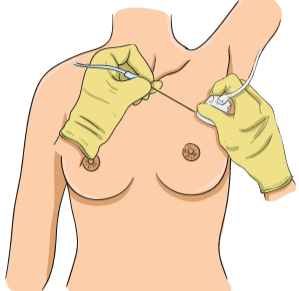
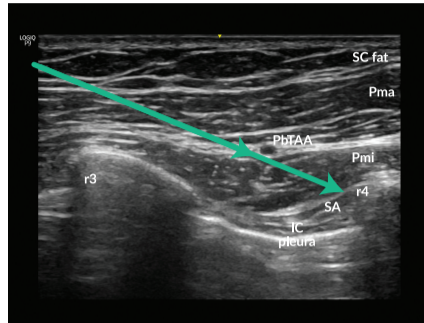
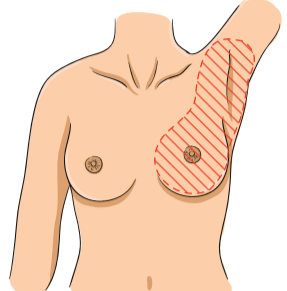
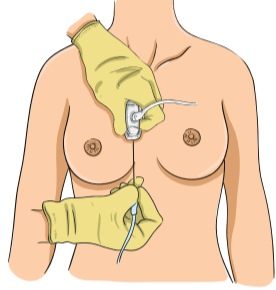
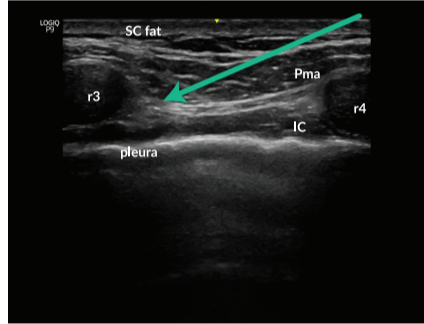
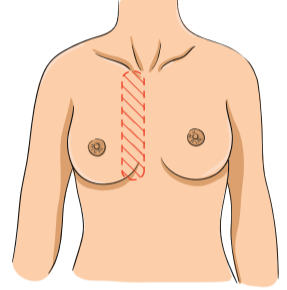
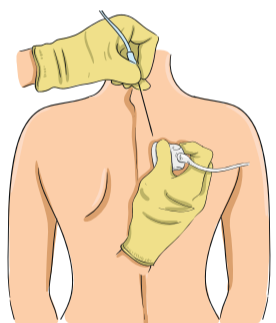
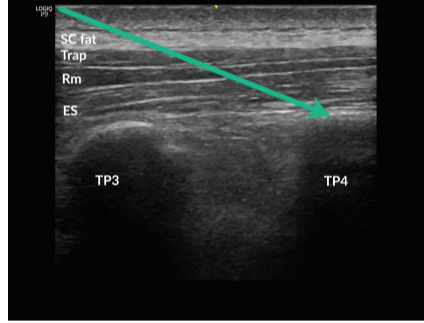
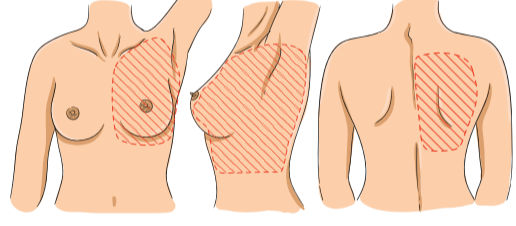
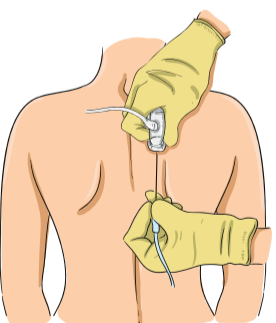
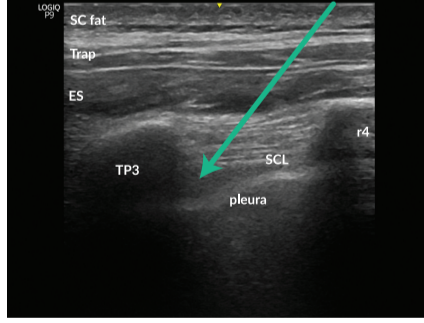
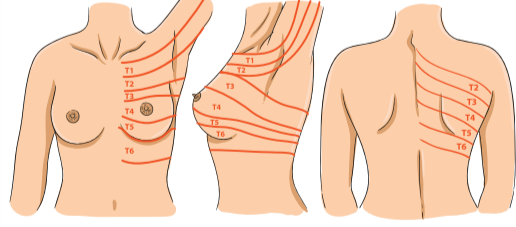


THORACIC WALL BLOCKS FOR BREAST CANCER SURGERY

Barbara Versyck, Kris Vermeylen, Renee van den Broek, Sari Casaer, Geert-Jan van Geffen

	PROBE AND NEEDLE	ULTRASOUND IMAGE	INDICATIONS														
<h2>PECS II</h2> <p>Patient position: supine, arm abducted Transducer: linear Needle: 22G, 5cm short bevel Local anesthetic: 20 + 20 ml</p> <p>ABBREVIATIONS</p> <table border="0"> <tr><td>Pma</td><td>Pectoralis major</td></tr> <tr><td>Pmi</td><td>Pectoralis minor</td></tr> <tr><td>SA</td><td>Serratus anterior</td></tr> <tr><td>IC</td><td>Intercostal</td></tr> <tr><td>r</td><td>rib</td></tr> <tr><td>SC fat</td><td>subcutaneous fat tissue</td></tr> <tr><td>PbTaa</td><td>Pectoral branch of thoraco acromial artery</td></tr> </table>	Pma	Pectoralis major	Pmi	Pectoralis minor	SA	Serratus anterior	IC	Intercostal	r	rib	SC fat	subcutaneous fat tissue	PbTaa	Pectoral branch of thoraco acromial artery	 <p>Transducer position: Place transducer under lateral third of clavicle, at level of third-fourth rib. Then, turn probe 45° clockwise. Needle approach: in plane from medial to lateral.</p>	 <p>Required view: r3 and r4 in combination with Pma, Pmi. If possible, with PbTaa and SA. Technique: needle insertion towards r4 aiming medial of PbTaa. First, lower injection (20ml) under Pmi. Then retract needle for upper injection (20ml) between Pma and Pmi. Spread of LA: linear fluid spread underneath Pmi and between Pma and Pmi. Avoid globular spread, which indicates intramuscular injection.</p>	 <p>Indications: unilateral breast and axillary analgesia. Tips: Aim needle at underlying rib to avoid pleura puncture. For breast surgery Pecs I + Serratus plane block at this level will give similar effect as Pecs II. Use 20ml + 20 ml to ensure sufficient spread in the axillary region.</p>
Pma	Pectoralis major																
Pmi	Pectoralis minor																
SA	Serratus anterior																
IC	Intercostal																
r	rib																
SC fat	subcutaneous fat tissue																
PbTaa	Pectoral branch of thoraco acromial artery																
<h2>SUBPECTORAL INTERFASCIAL PLANE</h2> <p>Patient position: supine Transducer: linear Needle: 22G, 5cm short bevel Local anesthetic: 20 ml</p> <p>ABBREVIATIONS</p> <table border="0"> <tr><td>Pma</td><td>Pectoralis major</td></tr> <tr><td>IC</td><td>Intercostal</td></tr> <tr><td>r</td><td>rib</td></tr> <tr><td>SC fat</td><td>subcutaneous fat tissue</td></tr> </table>	Pma	Pectoralis major	IC	Intercostal	r	rib	SC fat	subcutaneous fat tissue	 <p>Transducer position: place transducer parasagittal at level of r3-r4 rib, 2cm lateral to sternum. Needle approach: in plane from caudal to cephalad.</p>	 <p>Required view: r3 and r4 in combination with Pma. Technique: needle insertion aiming towards r3. Injection under Pma. Spread of LA: linear fluid spread underneath pectoralis major. Avoid globular spread, which indicates intramuscular injection.</p>	 <p>Indications: unilateral parasternal analgesia. Tips: Add to Pecs II block in case of medial breast surgery. Aim needle towards rib to avoid pleura puncture. The caudal to cephalad needle insertion prevents interference between the clavicle and the path of the needle insertion.</p>						
Pma	Pectoralis major																
IC	Intercostal																
r	rib																
SC fat	subcutaneous fat tissue																
<h2>ERECTOR SPINAE PLANE</h2> <p>Patient position: sitting, lateral or prone position Transducer: linear or curved depending on body posture (switch at TP depth +/- 4cm) Needle: 18G epidural Tuohy needle or 8-10cm short bevel needle Local anesthetic: 20-40 ml</p> <p>ABBREVIATIONS</p> <table border="0"> <tr><td>Trap</td><td>Trapezius</td></tr> <tr><td>Rhom</td><td>Rhomboides</td></tr> <tr><td>ES</td><td>Erector spinae</td></tr> <tr><td>TP</td><td>transverse process</td></tr> <tr><td>SC fat</td><td>subcutaneous fat tissue</td></tr> </table>	Trap	Trapezius	Rhom	Rhomboides	ES	Erector spinae	TP	transverse process	SC fat	subcutaneous fat tissue	 <p>Transducer position: place transducer parasagittal at level of fourth spinous process, then move ±3cm lateral, visualising the transverse process. Needle approach: in plane, cephalad to caudal.</p>	 <p>Required view: TP3 and TP4 in combination with Trap, Rm and ES. Technique: needle insertion aiming towards top of TP4. Injection under ES. Spread of LA: linear fluid spread lifting the erector spinae muscle off the tip of the TP. Avoid globular spread, which indicates intramuscular injection.</p>	 <p>Indications: analgesia of unilateral thoracic wall T2-T6. Tips: higher volume generates broader spread, dilute LA with NaCl 0.9% if necessary.</p>				
Trap	Trapezius																
Rhom	Rhomboides																
ES	Erector spinae																
TP	transverse process																
SC fat	subcutaneous fat tissue																
<h2>PARAVERTEBRAL</h2> <p>Patient position: sitting position with arched back, lateral 'foetal' position or prone Transducer: linear or curved depending on body posture (switch at TP depth +/- 4cm) Needle: 18G epidural Tuohy needle or 8-10cm short bevel needle Local anesthetic: 10-20ml</p> <p>ABBREVIATIONS</p> <table border="0"> <tr><td>Trap</td><td>Trapezius</td></tr> <tr><td>ES</td><td>Erector spinae</td></tr> <tr><td>SCL</td><td>superior costotransverse ligament</td></tr> <tr><td>TP</td><td>transverse process</td></tr> <tr><td>SC fat</td><td>subcutaneous fat tissue</td></tr> </table>	Trap	Trapezius	ES	Erector spinae	SCL	superior costotransverse ligament	TP	transverse process	SC fat	subcutaneous fat tissue	 <p>Transducer position: place transducer medial at level of third spinous process for parasagittal view, then move ±3cm lateral, visualising the transverse process. Needle approach: in plane, cephalad to caudal until.</p>	 <p>Spread of LA: lateral spread underneath superior costotransverse ligament, pushing the pleura down. Technique: needle insertion aiming towards SCL, then breach SCL to reach paravertebral space. Required view: TP superiorly, rib inferiorly, connected through SCL.</p>	 <p>Indications: unilateral analgesia of segmental somatosensory and sympathetic nerves without axilla. Tips: Rotate caudad part of US beam away from midline to optimize your ultrasound image. Due to the steep angulation of the needle, visualisation of needle tip may be challenging, use an echogenic needle. Perform the block at a mid-dermatomal level with reference to the surgical site, T3-4 for simple mastectomy. When greater dermatomal spread is desired, perform multilevel injections.</p>				
Trap	Trapezius																
ES	Erector spinae																
SCL	superior costotransverse ligament																
TP	transverse process																
SC fat	subcutaneous fat tissue																

THE INNERVATION OF THE BREAST AND AXILLARY REGION

ABBREVIATIONS

MBCN	Medial brachial cutaneous nerve
ICBN	Intercostobrachial nerve
LTN	Long thoracic nerve
MPN	Medial pectoral nerve
LPN	Lateral pectoral nerve

